PATHOLOGICA 2019;111:24-30; doi: 10.32074/1591-951X-41-17

Original Article

Histopathological assessment of prognostic factors in pancreatic resection specimens using a standardised protocol

A. Silvanto, T. Balamurugan, I.N. Bagwan

Departments of Histopathology, Surrey Pathology Services, Frimley Park and Royal Surrey County Hospitals, Guildford, UK

Summary

Background. Adenocarcinoma involving the pancreas shows differences in prognostic parameters including resection margin status depending on subtype.

Aim: To assess the reported incidence of each type and the rate of R1 resection using detailed histopathological examination protocol.

Methods. All pancreaticoduodenectomies between June 2011 and June 2013 at our institute were analysed. These were classified according to the site of origin, R1 status, size, stage at resection, lymph node status and the rate of lymphovascular and perineural invasion.

Results. 58 adenocarcinomas included 23 ductal, 16 intraductal papillary mucinous neoplasm (IPMN) related, 8 duodenal, 7 ampullary and 4 distal common bile duct (CBD) tumours. The CBD, pancreatic ductal and IPMN-related adenocarcinomas had the highest rates of R1 resection, at 75%, 69.5 and 62.5%, with the posterior and SMV margins most frequently involved. Ampullary adenocarcinoma had lower rates of R1 resection (14%) as well as perineural invasion (0%).

Conclusion. Ampullary adenocarcinomas had a lower rate of R1 resection and perineural invasion, both of which are parameters associated with a poorer outcome. This correlates with literature indicating ampullary tumours have a better prognosis. Our study also highlights the high rate of detection of microscopic margin involvement when a detailed histopathological examination protocol is employed.

Key words

Adenocarcinoma • Resection margin

Introduction

Adenocarcinoma of the pancreas has generally a very poor prognosis, presenting at a late stage. Even in cases amenable to resection, the rate of margin positivity ranges from 20-80% [1] and the overall survival is poor. Adenocarcinomas affecting the pancreas can be divided into ampullary adenocarcinomas, cholangiocarcinomas arising from intrapancreatic bile ducts and ductal type adenocarcinomas. Adenocarcinomas arising from intraductal papillary mucinous neoplasms (IPMN) can be viewed as a further category. Furthermore, duodenal adenocarcinomas can infiltrate into the pancreas. These various entities differ in terms of their prognosis, likelihood of margin involvement and the presence of other pathological features of tumour aggression, with ampullary adenocarcinomas having a more favourable outcome [2]. The accurate assessment of these parameters have been in the past hampered by difficulties in distinction between the different sites of origin, with distal bile duct cancer often underestimated [3]. Furthermore, until a few years ago, the pathological assessment of pancreatic resection was less standardised. The introduction of a more detailed protocol, as described by Menon et al. [4], has led to an increased rate of R1 resections, which is of prognostic significance. This combined with more accurate determination of site of origin should result in more accurate data on prognostic parameters and survival accordingly in each subtype.

How to cite this article: Silvanto A, Balamurugan T, Bagwan IN. *Histopathological assessment of prognostic factors in pancreatic resection specimens using a standardised protocol.* Pathologica 2019;111:24-30. https://doi.org/10.32074/1591-951X-41-17

Correspondence: Izhar Bagwan, Department of Histopathology, The Royal Surrey County Hospital, Egerton Road, Guildford, GU2 7XX, UK - E-mail: izhar.bagwan@nhs.net

© Copyright by Società Italiana di Anatomia Patologica e Citopatologia Diagnostica, Divisione Italiana della International Academy of Pathology OPEN ACCESS

In this study we aimed to determine the rate of margin involvement and the presence of adverse parameters according to the site of origin.

Materials and methods

Case selection. All pancreatic resections, including Whipple's resections and pylorus preserving pancreaticoduodenectomies, performed during a two year period from June 2011 to June 2013 were identified on the histopathology Winpath database. The histology H & E slides were reviewed to confirm the site of origin of adenocarcinoma which were categorised as ampullary, distal common bile duct, ductal, duodenal and those arising from an IPMN. Histological subtyping was performed using WHO classification of Tumours. Data was collected on the following parameters: Differentiation, size, rate of R1 resection (defined below), site of margin involvement, pT stage, lymph node status and rate of lymphovascular and perineural involvement. R1 resection was defined as < 1 mm from the SMV and posterior pancreatic resection margins and the pancreatic transaction margin, and 0 mm from the anterior pancreatic surface [5]. Demographic data (age & sex) was obtained from the medical records.

Pathological assessment (Tab. I). At our institution, we follow a standardised and detailed protocol when handling pancreatic resection (Fig. 1A). The pancreatic surfaces and margins are inked routinely with green for anterior surface, black for posterior margin, blue for SMV groove resection margin and red for pancreatic transaction margin. Additionally, prior to slicing the pancreas, the common hepatic duct/ CBD is opened and yellow ink applied to a probe is passed into the common bile duct, reaching its intrapancreatic portion. This aids subsequent determination of the site of origin by allowing more definite distinction between the intrapancreatic common bile duct (inked) and the main pancreatic duct (unlinked). After sampling the pancreatic and common bile duct/common hepatic duct and proximal and distal gastric/duodenal transaction margins, the pancreas is serially, thinly sliced in the axial plane perpendicular to the long axis of the duodenum from superior to inferior, in the periampullary plane and embedded as whole mount sections, ensuring thorough sampling of all resection margins identified by differential inking system (Fig. 1B-E). The lymph nodes are grouped as anterior and superior group, and posterior and inferior group including the nodes along the superior mesenteric vein and artery surface.

Determination of site of origin. The slides were reviewed, regardless whether the site of tumour origin was specified in the original report, and the site of origin was determined by considering the centre of the tumour mass, its location relative to local anatomy and the presence of an in situ lesion, including bile duct dysplasia of the CBD or pancreatic ductal system (BiIIN or PanIN), IPMN or adenomatous dysplasia of the duodenum [6]. The application of ink to common bile duct further aided the distinction between distal CBD, ampullary and pancreatic ductal subtypes.

Results

Demographic and histopathological data (Figs. 1, 2). Over a two year period, 95 pancreatic resections were performed at our hospital, including 58 cases of ade-

Tab. I. Standardised protocol for histopathological assessment of pancreatic resection specimens.

1. Examine and measure the size of different organs included in the specimen, for eg: duodenum, pancreas, distal stomach, gall bladder and common bile duct.
2. Open the duodenum and assess the ampulla and duodenum for tumours, polyps or ulcer.
3. Using the standardised protocol ink the specimen as: - anterior pancreatic surface: green - posterior pancreatic margin: black - superior mesenteric groove (SMV) margin: blue - pancreatic transaction margin: red - open the common bile duct/common hepatic duct and pass yellow ink through it using a probe.
4. The duodenal, common hepatic duct and the pancreatic transaction margins are submitted.
5. Following inking, the specimen is sliced in the axial plane into transverse sections from proximal to distal. The slices should include all of the inked resection margins and serosal surface.
6. The site of the tumour should be identified in the slices (either pancreatic duct/ head, distal common bile duct- intrapancreatic/ extrapancreatic, ampulla or duodenum) and 2-3 megablocks should be submitted along with a few small blocks of tumour.
7. All the fat around pancreas should be submitted for lymph nodes and the lymph nodes are grouped as anterior and superior pancreaticoduodenal lymph nodes, posterior and inferior pancreaticoduodenal lymph nodes including the superior mesenteric group and the common hepatic/common bile duct lymph nodes. Perigastric lymph nodes if present should be submitted separately.
8. Gall bladder, if present, should be sampled accordingly.

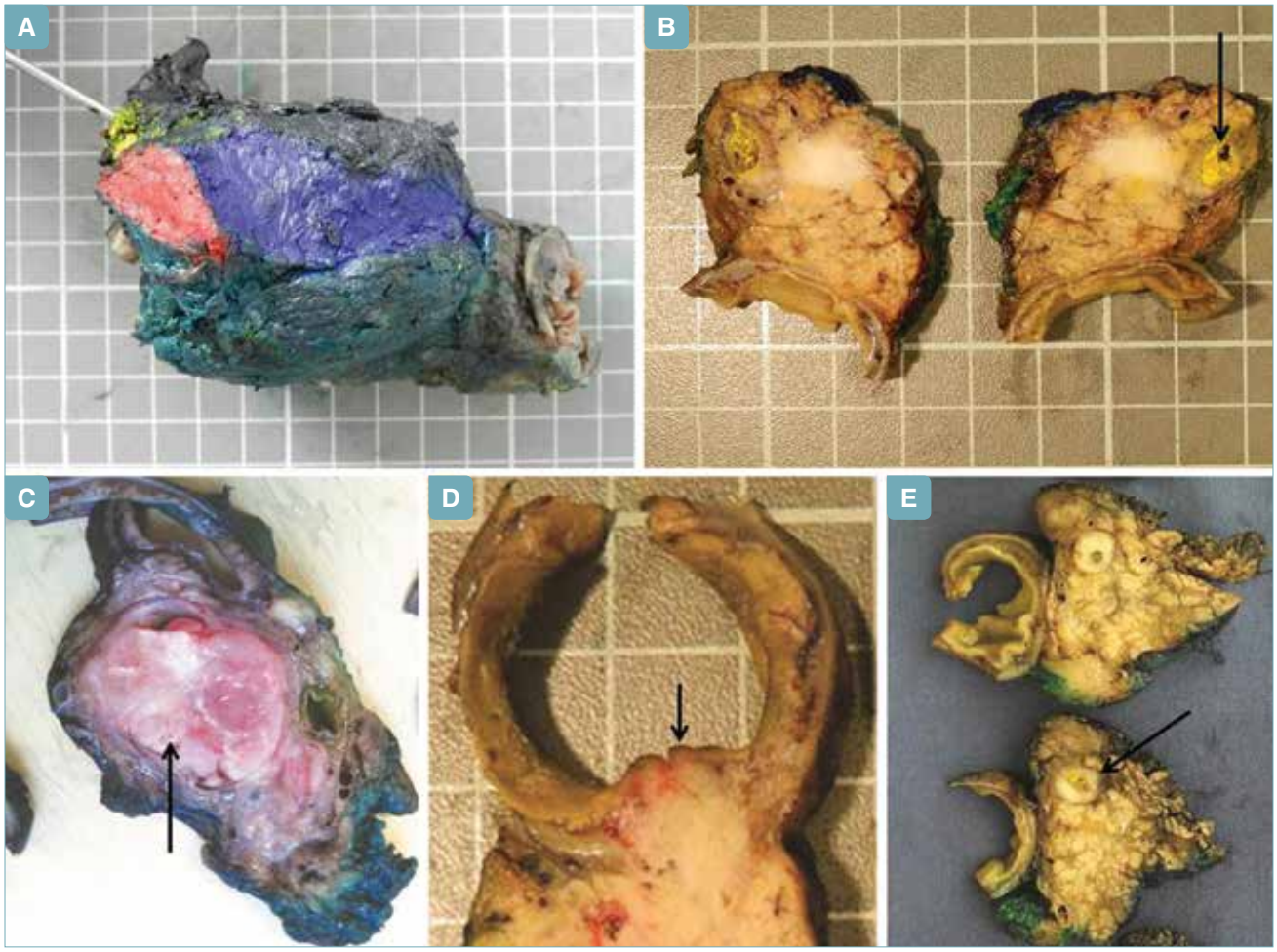

Fig. 1. A) Macroscopic photograph of a pancreaticoduodenectomy specimen demonstrating standardised inking protocol, including application of ink into common bile duct. **B)** Serial axial section demonstrating yellow ink within intrapancreatic distal common bile duct and firm irregular white tumour in the adjacent pancreas. **C)** An axial section of pancreas showing an intraductal solid tumour within the main pancreatic duct (marked by arrow). **D)** An axial section revealing an ampullary tumour (marked by arrow). **E)** Macroscopic photograph of a pancreaticoduodenectomy demonstrating serial axial slicing and revealing a circumferential firm white tumour within the distal common bile duct with yellow ink (marked by arrow).

nocarcinoma and 37 benign cases (Tab. II). The cohort with adenocarcinoma included 24 female and 34 male patients with an age range of 39-81.

The histopathological data is summarised in Table III. The 58 adenocarcinomas included 23 ductal (39.6%), 16 arising from a background IPMN (27.6%), 8 duodenal (13.8%), 7 ampullary (12.1%) and 4 distal common bile duct (6.9%, including 3 intrapancreatic and 1 extrapancreatic) adenocarcinomas. The primary pancreatic adenocarcinomas were more likely to be poorly differentiated (ampullary 86%, distal CBD 75%, invasive IPMN 75%, ductal 65%) compared to duodenal adenocarcinomas (38% poorly differentiated). Ductal, IPMN-related and duodenal adenocarcinomas had a similar mean diameter at 26 mm (16-40), 27.7 mm (5-40) and 27.9 mm (14-45), respectively, whereas ampullary and distal CBD were smaller at 13 mm (5-21) and 15.75 mm (11-20), respectively.

IPMN-related adenocarcinoma: The anatomical site of origin was pure main duct in 4 of 16 cases, side-branch in 3 of 16 cases whereas the remaining 9 showed combination of both anatomical sites. The background IPMN showed varied morphological patterns, commonest being intestinal type (9/16) followed by gastric type (3/16), oncocytic type (3/16) and one pancreaticobiliary type. The most common histological pattern of invasive tumour was tubular (15/16) and only one was pure mucinous/ colloid type.

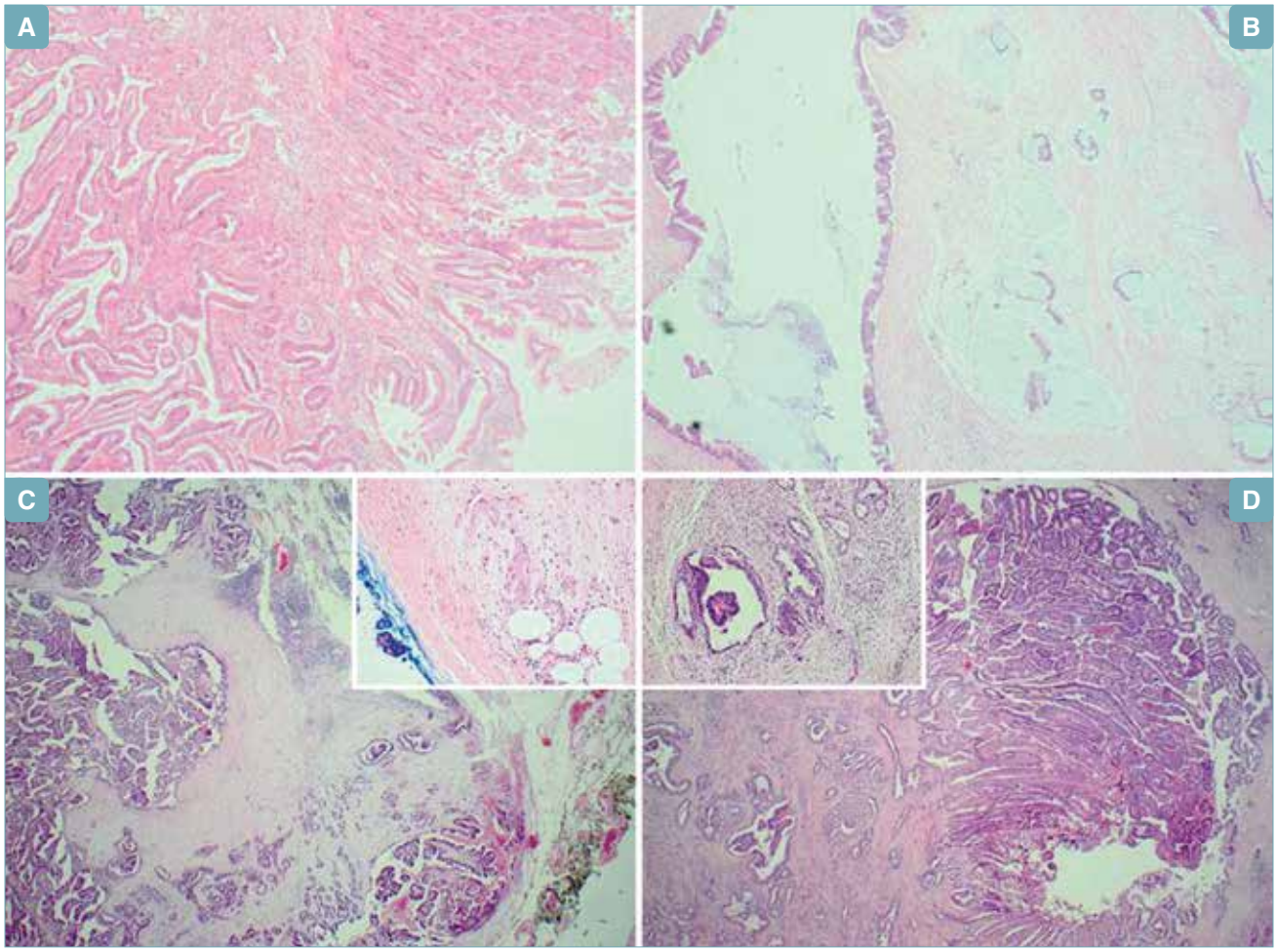

Fig. 2. A) Moderately differentiated ampullary adenocarcinoma undermining normal duodenal mucosa (H & E 40X). **B)** Mucinous adenocarcinoma arising from an IPMN with intestinal type morphology (H & E 40X). **C)** Moderate to poorly differentiated adenocarcinoma, < 1 mm from the posterior margin indicating R1 resection (H & E 40X). Inset: the carcinoma is < 1 mm from SMV margin (H & E 400X). **D)** Cholangiocarcinoma arising from the intrapancreatic portion of the distal common bile duct (H & E 40X). Inset: note the perineural invasion (H & E 200X).

Resection margin involvement (Fig. 2C). The CBD, pancreatic ductal and IPMN-related adenocarcinomas had the highest rates of R1 resection, at 75%, 69.5 and 62.5% respectively. Only 1 of 7 ampullary cases (14%) and none of duodenal adenocarcinomas (0%) had positive margins. The most frequently involved margins in ductal adenocarcinomas were the SMV groove and posterior margins (11/23). In the distal intrapancreatic CBD tumours the posterior margin was most commonly involved (2/3), and in the extrapancreatic CBD tumour the circumferential resection margin was involved (1/1). In the single R1 ampullary tumour resection, the posterior margin was positive. Regarding IPMN-related adenocarcinomas, SMV (7/16), posterior (4/16) and pancreat-

Tab. II. Histological diagnosis in 95 pancreatic resections.

Diagnosis	Number of cases (n = 95)
Adenocarcinoma	58
Non-invasive IPMN	9
Chronic pancreatitis, stones	9
Tubular or tubulovillous adenoma of duodenum	8
Autoimmune pancreatitis	3
Gangliocytic paraganglioma	2
Neuroendocrine tumour (one pancreatic, one duodenal)	2
Pseudocyst	1
Solid pseudopapillary neoplasm	1
Microcystic cystadenoma	1
Common bile duct dysplasia	1

ic transaction margins (4/16) were most frequently involved by invasive tumour. Of the 4 IPMN-related carcinoma cases with positive pancreatic transaction margin, 2 were side-branch origin and 2 showed combined main duct/ side branch origin; all 4 showed tubular growth pattern of invasive tumour with lymphovascular and perineural invasion. In these 4 cases, frozen section of the involved margin had not been performed at the time of operation. 4 additional cases of IPMN showed low grade dysplasia at the pancreatic transaction margin.

TNM stage. All the cases from 2011 to 2013 included in the study have been reported using the TNM 7th Edition for staging. Ductal, IPMN related and CBD adenocarcinomas were more frequently of a higher T stage (pT3 100%, 87.5% and 75% respectively). Most ampullary adenocarcinomas were resected at pT1/2 stage (86%). 63% of duodenal adenocarcinomas were pT3/4. A high rate of nodal involvement (pN status) was detected in all sites of origin, ranging from 63% (duodenal) to 100% (CBD). The lymph node ratio was greatest in ductal and IPMN-related carcinomas, but the differences to the other subtypes were small (all less than 0.2). The single IPMN-related mucinous/ colloid carcinoma was small size, of lower stage (pT1) and did not show lymph node metastasis.

Lymphovascular and perineural invasion (Fig. 2D inset). A high rate of LVI and PNI were detected in CBD (100% and 100%), ductal (87% and 100%) and IPMN related adenocarcinomas (81% and 100%). The incidence of LVI and PNI was lower in ampullary (57% and 0%) and duodenal (50% and 38%) adenocarcinoma.

Discussion

Site of origin. The distinction of adenocarcinomas involving the pancreas according to the site of origin is of clinical importance, as ampullary and duodenal adenocarcinomas have a more favourable prognosis with greater survival compared with ductal adenocarcinoma [7 2]. A study by Hatzaras et al. [2] described a series of 346 pancreatoduodenectomies for periampullary malignancies, of which 249 were pancreatic, 79 ampullary and 18 extrapancreatic cholangiocarcinomas. Our incidence of ductal, ampullary and CBD cancers parallels this incidence. However, in our study we have included carcinomas arising from IPMNs and the duodenum. A recent review article by Verbeke et al. highlighted the wide variation in the published incidence in pancreatic (33-89%), ampul-

Tab. III. Histopathological findings according to tumour site of origin.

Tumour origin	Ampullary	Distal CBD	Pancreatic Ductal	IPMN	Duodenal
Number (total 58)	7 (12.1%)	4 (6.9%)	23 (39.6%)	16 (27.6%)	8 (13.8%)
Grade	G2 = 1 G3 = 6	G2 = 1 G3 = 3	G2 = 8 G3 = 15	G2 = 4 G3 = 12	G1 = 1 G2 = 4 G3 = 3
Average size(mm)	13 (5-21)	15.75 (11-20)	26.0 (15-40)	27.7 (5-40)	27.9 (14-45)
R1	1/7 (14.3%)	3/4 (75%)	16/23 (69.5%)	10/16 (62.5%)	0
Involved margin by invasive tumour	Post = 1	Post = 2 CRM = 1	SMV = 11 Post = 11 Ant = 2 PTM = 1	SMV = 7 Post = 4 PTM = 4	0
pT	pT1 = 2 pT2 = 4 pT4 = 1	pT2 = 1 pT3 = 3	pT3 = 23	pT1 = 1 pT2 = 1 pT3 = 14	pT1 = 2 pT2 = 1 pT3 = 2 pT4 = 3
pN (metastatic nodes)	5/7 (71.4%)	4/4 (100%)	19/23 (82.6%)	11/16 (68.75%)	5/8 (63%)
Node ratio	0.14	0.11	0.19	0.18	0.15
LVI	4/7 (57%)	4/4 100%	20/23 (87%)	13/16 (81%)	4/8 (50%)
PNI	0/7 0%	4/4 100%	23/23 (100%)	16/16 (100%)	3/8 (38%)

(Post = posterior, CRM = ductal cirumferential resection margin, SMV = superior mesenteric vein groove resection margin, ant = anterior resection margin, PTM = pancreatic transaction margin, LVI = lymphovascular invasion, PNI = perineural invasion).

lary (5-42%) and distal bile duct (5-38%) cancers, indicating that many pathologists find determining the site of tumour origin difficult [1 6]. Case review by more experienced pancreatic pathologists can result in reclassification of a substantial number of cases, as found by Pomianowska et al. who discovered that distal bile duct cancers were most frequently misdiagnosed, particularly as an ampullary carcinoma [3]. As the prognosis differs with the various sites of origin, accurate allocation is important. At our centre we consider the centre of tumour bulk, proximity to local anatomical structures as well as the presence of any in situ or dysplastic component to aid in this distinction. Furthermore, the modification of the standardised protocol by the application of ink into the common bile duct aided in this process further.

R1 status and site of margin involvement. The review by Verbeke also focused on the wide range of published rates of microscopic margin involvement (R1), ranging from 0 to 85%, with R1 rates also depending on the site of tumour origin, where ampullary tumours had the lowest R1 rate at 0-27%, compared with 18-85% and 0-72% for pancreatic and distal bile duct cancers, respectively [1]. Microscopic resection margin involvement has been shown to impact adversely on survival indicating that the accurate assessment of the R status is of high importance [4 8-12]. Our study demonstrates a high incidence of R1 resection in ductal (69.5%), IPMN-related (62.5%) and CBD (75%) tumours, with much lower rate in ampullary (14%) and duodenal (0%) adenocarcinomas. This reflects a through pathological assessment as detailed above. The most frequently involved resection margins are similar to those described by Verbeke, with posterior margin most commonly involved in CBD and ampullary tumours. Ductal and IPMN-related adenocarcinomas most frequently had positive SMV and posterior margins. IPMN-related tumours had the highest R1 rate (presence of invasive tumour) at the pancreatic transection margin (4 of 16 cases). A reported rate of 45% of dysplasia at PTM has been described previously and this was associated with an increased rate of recurrence [13].

Markov et al. discuss the utility of frozen section examination in assessment of pancreatic neck transaction margin, wherein, if positive the resection can be extended more laterally to achieve a negative margin. However, this is not possible in other margins as the limit of dissection has already been reached [11]. Kooby et al., in their large Central Pancreas Consortium study of 1399 patients, demonstrated a median overall survival of 21 months in R0 resections as compared to 13.7 months in resections with R1 pancreatic neck margin and 11.9 months with an R1-converted-to-R0-pancreatic neck margin (both $P < 0.001$), thus questioning the use of routine frozen section analysis of these specimens [14]. Similar findings were also observed by Lad NL et al. who concluded that extending the neck resection after a positive frozen section to achieve R0 margin status did not appear to improve the overall survival [15]. In present study, frozen section examination had not been performed in cases with R1 pancreatic neck margin.

Tumour size and stage. In our study, the average tumour size was greatest for ductal, IPMN related and duodenal adenocarcinomas and smallest for ampullary and CBD tumours, reflecting their tendency for earlier presentation. This parallels the findings of Hatzaras et al. [2] who found that resected pancreatic cancers tended to be larger than cholangiocarcinomas or ampullary cancers. In our cohort, ampullary tumours were also less advanced locally, with 86% resected at either T1 or T2 stage. This was in contrast with the other tumour sites, where a high proportion of tumours were resected at pT3.

Lymph node status. Lymph node involvement, particularly a lymph node ratio of greater than 0.2, has been reported to be the strongest prognostic factor after resection of pancreatic cancer [16 17]. Furthermore, in ampullary cancers, when controlled for tumour stage, the presence of nodal metastasis predicted poor survival [2]. We found a high rate of nodal involvement in tumours from all sites, highest rate in CBD tumours (100%) and ductal adenocarcinomas (82.6%) and lower in ampullary (71.4%), IPMN-related (68.75%) and duodenal (63%) tumours. The lymph node ratio was greatest in ductal and IPMN-related carcinomas, but the differences to the other subtypes were small (all less than 0.2). Lymph node involvement has been reported to be more frequent in pancreatic (75%) than ampullary (48%) and CBD tumours (57%) [17]. Our findings are not entirely in agreement with this; however, our small sample size may partly explain the discrepancy.

Perineural and lymphovascular invasion (LVI). Perineural invasion has been shown to represent a second independent adverse prognostic factor, in addition to lymph node status [2]. The rate of perineural invasion in our study was highest in ductal, IPMN and CBD tumours (95-100%), and much lower in duodenal (38%) and ampullary (0%) tumours. This is in concordance with the findings of Hatzaras et al. [2], who reported less frequent perineural invasion in ampullary cancers. The evidence for the prognostic value of lymphovascular invasion is less robust. We found highest rates of LVI in CBD, ductal and IPMN tumours, and lower rates in ampullary and duodenal tumours.

Conclusion

Finally to conclude, our study provides further evidence that the rate of R1 resection in adenocarcinoma of the pancreas is high when a systematic and through histopathological examination is employed. It also further highlights that the R1 rate varies between sites of origin, being most frequent amongst CBD, ductal and IPMN-related adenocarcinomas. Determining the exact site of origin is important as prognosis differs and allocation of patients into various clinical trials is dependent on the histological type of adenocarcinoma. Our modification of the current standardised protocol, i.e. the technique of applying ink through the CBD, further aids in this process. Our data also correlates with existing literature in terms of ampullary tumours being smaller, of lower stage at resection and exhibiting a somewhat lower rate of lymph node involvement and perineural and lymphovascular invasion.

Conflict of interest statement

None declared.

References

1. Verbeke CS, Glaudhaug IP. *Resection margin involvement and tumour origin in pancreatic head cancer*. Br J Surg 2012;99:1036-49.
2. Hatzaras I, George N, Muscarella P, et al. *Predictors of survival in periampullary cancers following pancreaticoduodenectomy*. Ann Surg Oncol 2010;17:991-7.
3. Pomianowska E, Grzyb K, Westgaard A, et al. *Reclassification of tumour origin in resected periampullary adenocarcinomas reveals underestimation of distal bile duct cancer*. Eur J Surg Oncol 2012;38:1043-50.
4. Menon KV, Gomez D, Smith AM, et al. *Impact of margin status on survival following pancreatoduodenectomy for cancer: the Leeds Pathology Protocol (LEEPP)*. HPB (Oxford) 2009;11:18-24.
5. Verbeke CS. *Resection margins in pancreatic cancer*. Surg Clin North Am 2013;93:647-62.
6. Bledsoe JR, Shinagare SA, Deshpande V. *Difficult diagnostic problems in pancreaticobiliary neoplasia*. Arch Pathol Lab Med 2015;139:848-57.
7. Sarmiento JM, Nagomey DM, Sarr MG, et al. *Periampullary cancers: are there differences?* Surg Clin North Am 2001;81:543-55.
8. Rau BM, Moritz K, Schuschan S, et al. *R1 resection in pancreatic cancer has significant impact on long-term outcome in standardized pathology modified for routine use*. Surgery 2012;152(3 Suppl 1):S103-11.
9. Konstantinidis IT, Warshaw AL, Allen JN, et al. *Pancreatic ductal adenocarcinoma: is there a survival difference for R1 resections versus locally advanced unresectable tumours? What is a 'true' R0 resection?* Ann Surg 2013;257:731-6.
10. Fatima J, Schnelldorfer T, Barton J, et al. *Pancreatoduodenectomy for ductal adenocarcinoma. Implications of positive margin on survival*. Arch Surg 2010;145:167-72.
11. Markov P, Satoi S, Kon M. *Redefining the R1 resection in patients with pancreatic ductal adenocarcinoma*. J Hepatobiliary Pancreat Sci 2016;23:523-32.
12. Ethun CG, Kooby DA. *The importance of surgical margins in pancreatic cancer*. J Surg Oncol 2016;113:283-8.
13. Frankel TL, LaFemina J, Bamboat ZM, et al. *Dysplasia at the surgical margin is associated with recurrence after resection of non-invasive intraductal papillary mucinous neoplasms*. HPB (Oxford) 2013;15:814-21.
14. Kooby DA, Lad NL, Squires MH 3rd, et al. *Value of intraoperative neck margin analysis during Whipple for pancreatic adenocarcinoma: a multicenter analysis of 1399 patients*. Annals Surg 2014;260:494-501.
15. Lad NL, Squires MH, Maithel SK, et al. *Is it time to stop checking frozen section neck margins during pancreaticoduodenectomy?* Ann Surg Oncol 2013;20:3626-33.
16. Riediger H, Keck T, Wellner U, et al. *The lymph node ratio is the strongest prognostic factor after resection of pancreatic cancer*. J Gastrointest Surg 2009;13:1337-44.
17. Pomianowska E, Westgaard A, Mathisen O, et al. *Prognostic relevance of number and ratio of metastatic lymph nodes in resected pancreatic, ampullary, and distal bile duct carcinomas*. Ann Surg Oncol 2013;20:233-41.

Received: December 29, 2017 - Accepted: November 24, 2018